



EPiC Series in Health Sciences

Volume 3, 2019, Pages 338–343

CAOS 2019. The 19th Annual Meeting of the International Society for Computer Assisted Orthopaedic Surgery



Usability and Accuracy assessment of an innovative low dose C-arm with 2D fluoroscopy, 3D imaging and real-time navigation in a single platform for spine surgery – a cadaveric experimentation

John Sledge¹, MD; Stephane Lavallee², PhD; Sophie Genna²; Laurence Chabanas²;

¹ Lafayette Bone and Joint Clinic, Lafayette, LA

² Surgivisio / eCential, Grenoble France

josledge@lbjclinic.com, stephane.lavallee@surgivisio.com,
sophie.genna@surgivisio.com, laurence.chabanas@surgivisio.com,

Abstract

Clinical benefits of intra-operative 3D imaging and surgical navigation are widely described in the literature. However, existing guidance systems are often reported as complex and time consuming^{1,2,4}. The Surgivisio / eCential system is an innovative intra-operative C-arm combining 2D fluoroscopy, 3D imaging and real time navigation capabilities within unified an all-in-one platform³. The aim of this cadaveric experimentation is to evaluate the usability of the system, and to assess pedicle screw placement using this novel device. Surgivisio / eCential device offers an all-in-one solution with a unique workflow and user interface. The embodiment used here is dedicated to any spinal procedures requiring insertion of a trocar inside a pedicle. The usability of the system is assessed by measuring the ability of the user to navigate the trocar and place k-wires percutaneously inside a group of pedicles.

The accuracy of screw placement is evaluated using post-operative 3D image of the implanted screw exported on an internally developed image visualization tool. The screw placement is assessed according to Gertzbein grading scale by the operator and two other evaluators. For each vertebrae group, fixation of the patient reference to the end of 3D

reconstruction was done in less than 10 minutes. The percutaneous navigation and placement of 6 k-wires in a vertebrae group could be performed in 28 minutes for the first 2 groups and in 22 minutes for the third group.

100% of screws was graded 0 on Gertzbein scale by all evaluators.

1 Introduction

Intra-operative 3D imaging and surgical navigation are two technologies widely spread in spine surgery. Clinical benefits of such systems are described in the literature, but existing guidance systems are often reported as complex and time consuming^{1,2,4}. The Surgivisio / eCential system is a unique intra-operative mobile C-arm device offering 2D fluoroscopy, 3D imaging and real time navigation capabilities within a unified platform³.

The purpose of this experimentation is to evaluate the usability of the system, and to assess pedicle screw placement using the system in a cadaver lab environment.

2 Material and methods

2.1 Material

The Surgivisio / eCential device (SURGIVISIO / eCENTIAL, France), is a unified solution offering 2D fluoroscopy, 3D imaging and real-time navigation capabilities, with a unique user interface, that has been previously introduced³. It can be used routinely, for any procedure requiring insertion of a trocar inside a bony structure.

A single use patient reference is attached percutaneously to the patient's spine at the level of interest. It is first used to support an imaging phantom with radio-opaque fiducial for image acquisition. An AP and a lateral x-ray images are used for optimization to allow the C-arm trajectory to be automatically computed around the volume of interest, maximizing the reconstruction volume, avoiding collisions with patient bed, and minimizing X-ray dose. The surgeon and surgical staff move outside the OR during the 3D spin. The 3D image reconstruction is then computed, with the automatic detection of the imaging phantom fiducials enabling auto-calibration of each individual x-ray projection.

An optical patient tracker is then exchanged on the patient reference by a precise and reproducible fixation. It can be removed for surgical ease, until it is required for navigation. It also has a reproducible breakaway mechanism, removing the risk for inadvertently displacing the tracker during the procedure. A pre-calibrated trocar equipped with a tracker can be immediately navigated in the 3D image, after a quick single-point check of the trocar tip. The system displays sagittal and axial reformatted slices showing the trajectory of the trocar inside the pedicle as it is inserted by the surgeon.

2.2 Usability of trocar navigation

The purpose of this experimentation is to evaluate the usability of the system with a surgeon having no clinical experience with the device. Our evaluation criterion is for the surgeon to be able to navigate the trocar and place k-wires percutaneously bilaterally in lumbar and thoracic pedicles, in a reasonable timeframe. A specimen is placed in prone position on a radio-lucent surgical bed.

9 vertebrae are divided in 3 groups for processing (Group 1 from L5 to L3, Group 2 from L2 to T12, Group 3 from T11 to T9). The steps of the operative technique described above are the same for each vertebrae group, resulting in bilateral k-wire placement for each vertebra (Figure 1).

For each vertebrae group, time is recorded from fixation of the patient reference to display of 3D reconstructed image, and then from navigation of the trocar for the first pedicle to the final placement of the last k-wire.

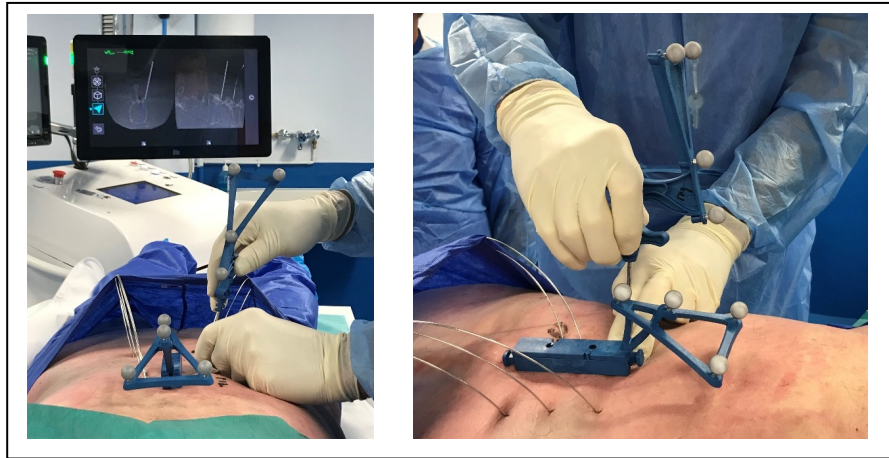


Figure 1 - Percutaneous trocar navigation and k-wire placement

2.3 Pedicle screw implantation

The purpose of the experimentation is to assess screw placement using the eCENTIAL device, according to Gertzbein grading. A second specimen is placed in prone position. The patient reference is fixed at the level of T9. The 3D imaging reconstruction process generates a volume covering from T7 to T11 and the trocar is navigated bilaterally on each of the five levels included in the image. Ten K-wires are placed, one at each trocar insertion. Cannulated pedicle screws are then implanted using k-wire guidance. The screws 3D position is assessed from a 3D control acquisition made after all screws have been implanted.

Post-op 3D image is exported, screw placement inside the pedicle is evaluated using an internally developed image visualization tool (Figure 2). The screw placement is assessed according to Gertzbein grading scale by the operator and two other evaluators.

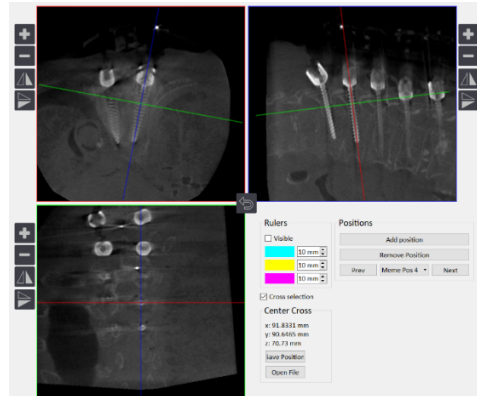


Figure 2 - Post processing screw placement assessment

3 Results

3.1 Usability experimentation report

The operator was able to successfully perform all the steps for all 3 vertebrae groups covering 9 levels:

- Percutaneous fixation of the patient reference in the spinous process
- 3D imaging of the spine
- Percutaneous navigation of the trocar inside the pedicles
- Placement of k-wires

For each vertebrae group, fixation of the patient reference to the end of 3D reconstruction was done in less than 10 minutes. The percutaneous navigation and placement of 6 k-wires in a vertebrae group could be performed in 28 minutes for the first 2 groups and in 22 minutes for the third group.

3.1 Pedicle screw implantation assessment

The grading assessment of the implanted screws from post-op 3D imaging volumes was consistent among all three evaluators and showed 10/10 Grade 0 screws.

4 Discussion

Spine surgery is probably the best candidate of orthopedic surgery that can benefit from new guidance technologies⁵. The contribution of 3D imaging in this discipline has been widely

demonstrated in the literature. However, connecting an imaging system to a separate navigation system requires complex procedures and can lead to cumulative error factors⁶. The Surgivisio / eCential device has been designed to offer ease of use, increased precision of the surgical procedure and a smooth surgical workflow. This in vitro test shows that the device allows quick and reliable handling of the tool, as well as a highly accurate screw placement. This represents a significant improvement over existing technologies, since usability of 3D imaging and navigation was known to be quite poor and probably underestimated. This increased usability, reliability and time savings is expected to open new doors to multiple applications in orthopaedics.

However, this experimentation has some limitations such as cadaver lab conditions, small number of specimens, small number of pedicle insertions and single operator. Further evaluation studies will be performed.

Conclusion

This study demonstrates performance and safety of the new Surgivisio / eCential device. Various spine procedures can benefit from this unified technology such as pain injection, vertebroplasty, instrumentation, SI joint fusion, tumor removal. In the future, it is expected to be extended to multiple CAOS applications.

Disclosure : John Sledge, MD is a consultant for Surgivisio

Reference

1. Myung-Hoon Shin, M.D., Kyeong-Sik Ryu, M.D., Ph.D., Chun-Kun Park, M.D., Ph.D.
Accuracy and Safety in Pedicle Screw Placement in the Thoracic and Lumbar Spines: Comparison Study between Conventional C-Arm Fluoroscopy and Navigation Coupled with O-Arm Guided Methods
J Korean Neurosurg Soc 52: 204-209, 2012
2. Myung-Hoon Shin, MD, Jung-Woo Hur, MD, Kyeong-Sik Ryu, MD, PhD, and Chun-Kun Park, MD, PhD
Prospective Comparison Study Between the Fluoroscopy-guided and Navigation Coupled With O-arm-guided Pedicle Screw Placement in the Thoracic and Lumbosacral Spines
J Spinal Disord Tech _ Volume 28, Number 6, July 2015
3. Stéphane Lavallée, Laurence Van Beek, David Armand, Arnaud Pierre, John Sledge, Lou Jenis, Jérôme Tonetti
Method of auto-calibration and auto-registration of an intra-operative 3D imaging system integrated with navigation
EPiC Series in Health Sciences Volume2, 2018, Pages127-129
4. Scott C. Wagner, Patrick B. Morrissey, Ian D. Kaye, Arjun Sebastian, Joseph S. Butler, Christopher K. Kepler

Intraoperative pedicle screw navigation does not significantly affect complication rates after spine surgery

J Clin Neurosci. 2018 Jan;47:198-201

5. David C. Noriega, PhD, Rubén Hernández-Ramajo, PhD, Fiona Rodríguez-Monsalve Milano, MD, Israel Sanchez-Lite, MD, Borja Toribio, MD, Francisco Ardura, PhD, Ricardo Torres, PhD, Raul Corredera, PhD, Antonio Kruger, PhD

Risk-benefit analysis of navigation techniques for vertebral transpedicular instrumentation: a prospective study

Spine J. 2017 Jan;17(1):70-75.

6. Yu-Mi Ryang, MD, PhD, Jimmy Villard, MD, MSc, Thomas Obermüller, Benjamin Friedrich, MD, Petra Wolf, Jens Gempt, MD, Florian Ringel, MD, PhD, Bernhard Meyer, MD, PhD

Learning curve of 3D fluoroscopy image-guided pedicle screw placement in the thoracolumbar spine