



PATIENT SPECIFIC INSTRUMENTS CAN ACHIEVE A BETTER SURGICAL ACCURACY THAN NAVIGATION ASSISTANCE IN JOINT-PRESERVING SURGERY OF THE KNEE JOINT: A CADAVERIC COMPARATIVE STUDY

S.E. Bosma PhD¹, P.C. Jutte MD², K.C. Wong³, L. Paul⁴, J. Gerbers²

^{1,2}University Medical Centre Groningen, 9700 RB Groningen, The Netherlands, sarah.bosma92@gmail.com

³Prince of Wales hospital, Hong Kong, Hong Kong

⁴3D-Side, Louvain-La-Neuve, Belgium

INTRODUCTION

Orthopaedic oncologic surgery requires resection with a safe margin as inadequate surgical margin leads to unfavorable results with an increased rate of local tumor recurrence [1]. Computer Navigation Assisted Surgery (CAS) and Patient Specific Instrumentation (PSI) have been reported to increase accuracy and predictability of tumor resections [2-6]. The technically demanding joint-preserving surgery that retains the native joint with the better function may be benefited from the new techniques [7]. CAS has the advantages of real-time intraoperative guidance of the bone resections but requires bulky and costly facilities [5]. PSI is a simple option of replicating surgical plan but lacks intraoperative image feedback on the surgery [5,6]. As primary bone sarcoma is uncommon, clinical studies for meaningful comparison of

the two techniques may not be feasible. The cadaver study was to investigate the surgical accuracy of CAS and PSI in joint-preserving tumor surgery of knee joint.

MATERIALS AND METHODS

CT scans of eight knees in four cadavers were performed. The CT images were imported into an engineering software (MIMICS, Materialise) for the 3D surgical planning of simulated, multiplanar joint-preserving resections for distal femur or proximal tibia metaphyseal bone sarcoma [Fig. 1]. Tumor surgeons defined the virtual resection plans that were then transferred to a CT-based navigation system (OrthoMap 3D, Stryker) for navigation planning by a method of CAD to DICOM conversion [8]. Engineers used the same virtual plans for the design and fabrication of the PSI. The design of the PSI consisted of cutting platforms with a contacting surface that conform to the bone contour next to the sites of planned resections. Each of the four techniques (freehand, CAS, PSI and CAS + PSI) was used in four joint-preserving resections for two knees of a cadaver. In the CAS+PSI technique, the navigation system helped confirm the correct placement of PSI before PSI-assisted bone resections. Post-resection CT images were co-registered with preoperative planning for comparative analysis. The location accuracy (the maximum deviation of distance between the planned and the achieved resections) and the time spent on the technique setup till the completion of the bone resections were measured. The results of the four methods were compared by using t-test (statistically significant if $P < 0.05$).

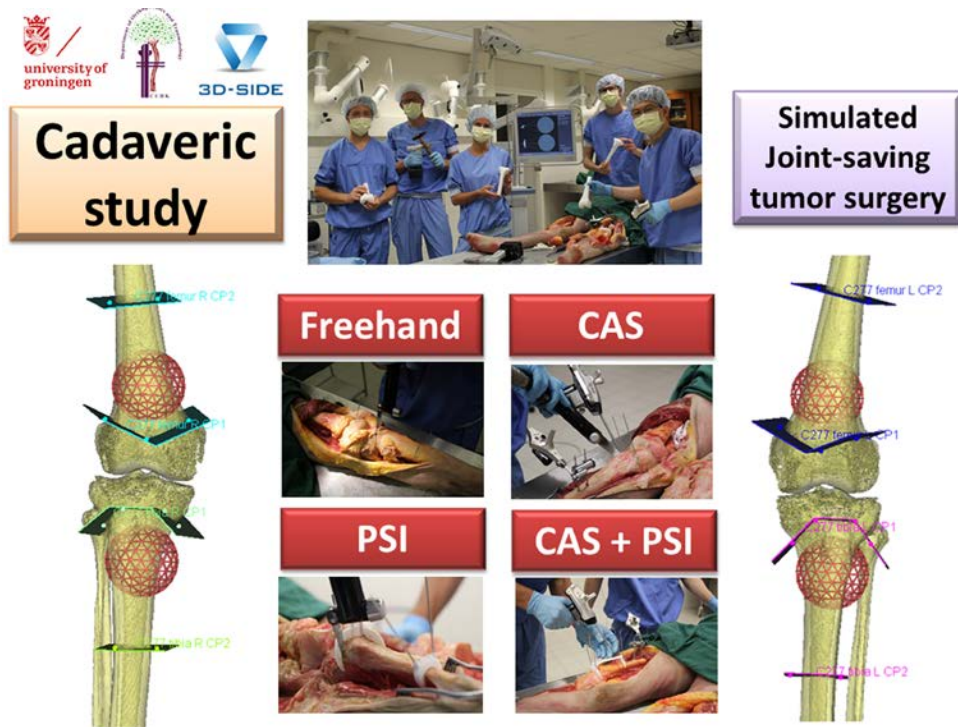


Figure 1 - On the left and on the right the 3D surgical planning of simulated, multiplanar joint-preserving resections for distal femur or proximal tibia metaphyseal bone sarcoma.

RESULTS

Both the CAS+PSI and PSI techniques could reproduce the planned resections with a mean location accuracy of < 2 mm while that of the CAS and freehand technique was 3.6 mm and 9.2mm respectively (Table 1). A significant difference was found in the location accuracy of the freehand technique with the other assisted techniques. There was no statistical difference between the CAS+PSI and the PSI techniques ($p=0.92$) but a significant difference between the CAS technique and the CAS+PSI ($p=0.042$) or PSI technique ($p=0.034$). The PSI technique took the lowest mean time of 4.78 ± 0.97 min for bone resections. This was significantly different from the CAS+PSI technique (mean 12.78 min; $p < 0.001$) and the CAS technique (mean 16.97 min; $p < 0.001$).

Cadaveric study	The four techniques used in joint preserving tumor surgery			
	Freehand	CAS	PSI	CAS + PSI
Mean location accuracy (mm)	9.16 ± 3.34	3.64 ± 2.1	1.91 ± 1.06	1.99 ± 1.04
Mean time for bone resections (minutes)	6.8 ± 1.12	16.97 ± 2.37	4.78 ± 0.97	12.78 ± 3.85

Table 1 - The results of the four techniques in joint preserving tumor surgery.

DISCUSSION

Up to date, it was the only cadaveric study of simulating joint-preserving tumor surgery around knee joints. Our results suggested that the CAS or PSI assisted techniques helped reproduce the planned multiplanar resections. The PSI method could achieve the most accurate bone resections (within 2mm error) with the least time for bone resections. It concurred with the results of a cadaveric study of comparing CAS and PSI in periacetabular tumor surgery [9]. Combining CAS with PSI technique might not improve surgical accuracy but might increase bone resection time. However, the PSI placement on the bone surface depends only on the subjective feeling of surgeons and also it may not apply if the extraosseous tumor component is large [5,9]. Combining CAS with PSI may address the limitations. Further clinical studies are needed to determine the clinical efficacy and indications of CAS or PSI techniques in joint-preserving tumor surgery.

REFERENCES

1. Bacci G, Ferrari S, Mercuri M, Bertoni F, Picci P, Manfrini M, Gasboarrini A, Forni C, Cesari M, Campanacci M. "Predictive factors for local recurrence in osteosarcoma: 540 patients with extremity tumors followed for minimum 2.5 years after neoadjuvant chemotherapy." *Acta Orthop Scand*. 1998;69:230-236.
2. Wong KC, Kumta SM. Computer-assisted tumor surgery in malignant bone tumors. *Clin Orthop Relat Res*. 2013; 471(3):750–61.
3. Gerbers JG, Stevens M, Ploegmakers JJ, Bulstra SK, Jutte PC. Computer-assisted surgery in orthopedic oncology. *Acta Orthop*. 2014 Dec;85(6):663-9.
4. Young, P. S.; Bell, S. W.; Mahendra, A. "The evolving role of computer-assisted navigation in musculoskeletal oncology" *The Bone & Joint Journal*. 2015 Feb;97-B(2);258–264.

5. Wong KC, Kumta SM, Sze KY, Wong CM. Use of a patient-specific CAD/CAM surgical jig in extremity bone tumor resection and custom prosthetic reconstruction. *Comput Aided Surg.* 2012;17(6):284–93.
6. Gouin F, Paul L, Odri GA, Cartiaux O. Computer-Assisted Planning and Patient-Specific Instruments for Bone Tumor Resection within the Pelvis: A Series of 11 Patients. *Sarcoma.* 2014;2014:842709.
7. Wong KC, Kumta SM. “Joint-preserving tumor resection and reconstruction using image-guided computer navigation.” *Clin Orthop Relat Res.* 2013;471:762–773.
8. Wong KC, Kumta SM, Leung KS, Ng KW, Ng EW, Lee KS. “Integration of CAD/CAM planning into computer assisted orthopaedic surgery.” *Comput Aided Surg.* 2010; 15(4-6): 66-74.
9. Wong KC, Sze KY, Wong IO, Wong CM, Kumta SM. Patient-specific instrument can achieve same accuracy with less resection time than navigation assistance in periacetabular pelvic tumor surgery: a cadaveric study. *Int J Comput Assist Radiol Surg.* 2016 Feb;11(2):307-16.